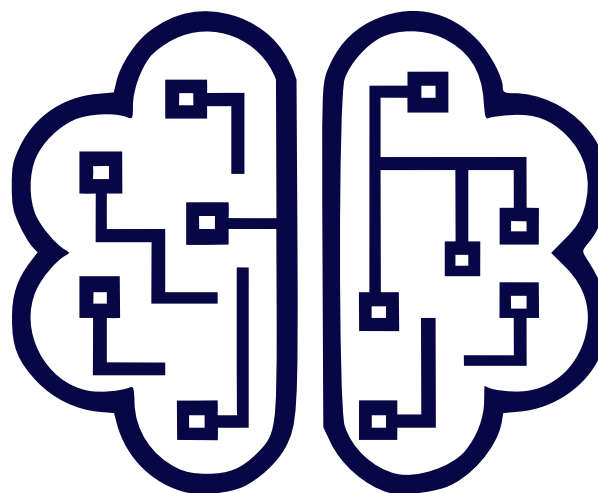

## TEAM Project

### Technologically Enabled Advancements in Dental Medicine

#### WP3 – Research activities

#### D3.2. Report on research activities

**Document type:** R - Report

**Date of issue:** M24

**Dissemination level:** PU

**Project duration:** 01.01.2024-30.06.2026

**Director:** Prof. Dr. Reinhilde Jacobs, KU Leuven, Belgium

*This project has received funding from the Government of Romania and the National Authority for Research (ANC) under the PNRR – Component C9, Investment I8, Contract PNRR-III-C9-2023-I8, CF.80/31.07.2023, No. 760235/28.12.2023.*

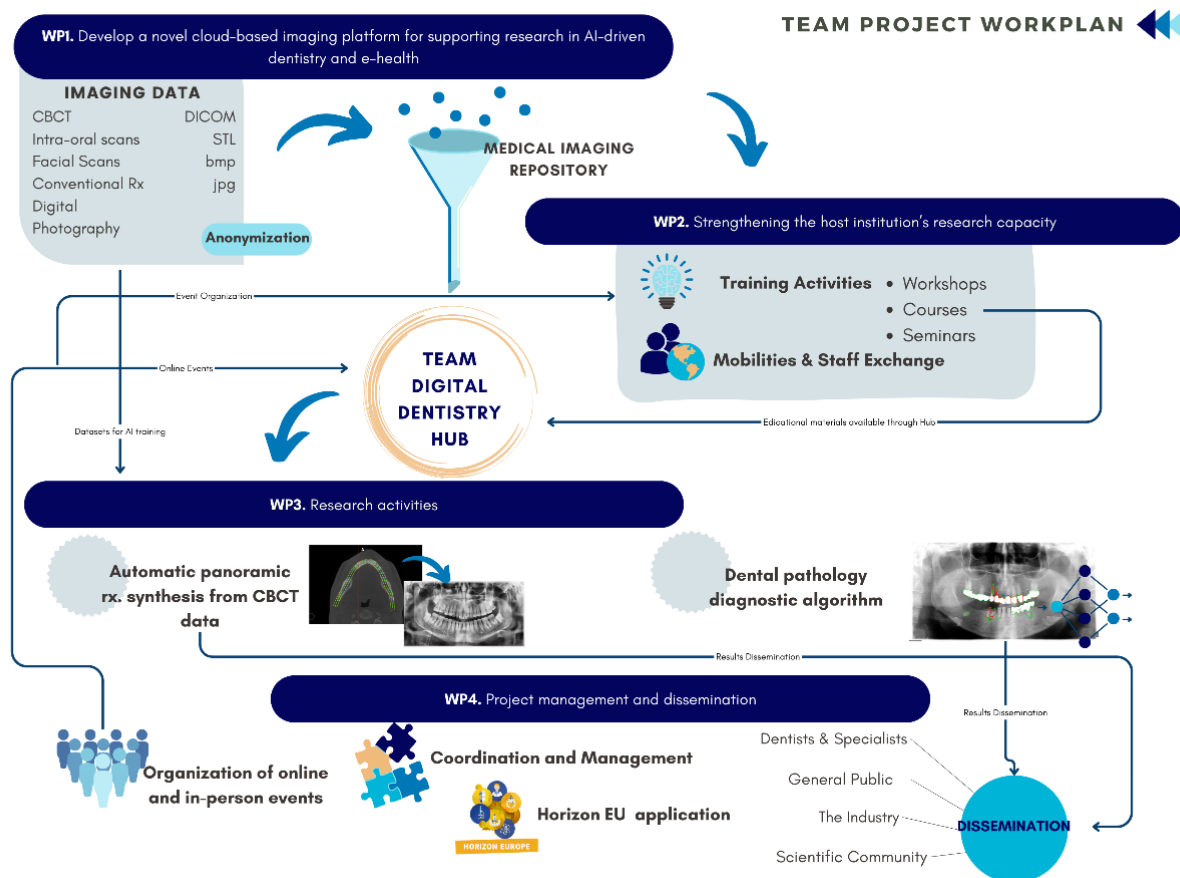
The TEAM Project aims to explore the integration of artificial intelligence (AI) into dentistry and maxillofacial surgery through the development of tools for pathology detection, clinical decision support, image segmentation, and digital surgical planning. By integrating AI into these areas, the project seeks to improve diagnostic accuracy, support personalized treatment approaches, and optimize clinical workflows.

This document presents the research activities carried out within the TEAM Project. The report summarizes the scientific activities developed within Work Package 3 (WP3), focusing on artificial intelligence applications for medical imaging and advanced computational methods for diagnosis and treatment planning.

Research activities evolved during the implementation period in accordance with the rapid development of artificial intelligence applications in dentistry and the intermediate results obtained within the project. These adaptations did not modify the original objectives of the project, but rather expanded the research directions related to the development, testing, and validation of AI-based systems for dentomaxillofacial imaging.

## I. Objectives

The objective of WP 3 - Research Activities was to strengthen the scientific and technological research capacity of the host institution through the development and validation of AI-based diagnostic tools and digital workflows for dentistry and maxillofacial surgery.



## II. Artificial Intelligence in the Diagnosis of Temporomandibular Disorders



Research activities were conducted to develop artificial intelligence-based tools for the automated assessment of temporomandibular disorders (TMDs) using MRI. The research focused on the identification and classification of temporomandibular joint (TMJ) disc displacement on oblique sagittal and coronal MRI sections.

A pilot study was carried out on a dataset consisting of MRI scans from 50 patients diagnosed with TMD. The dataset included 300 proton density (PD) MRI sections obtained from bilateral sagittal and coronal acquisitions in open- and closed-mouth positions. The images were manually annotated by experienced clinicians and used for the development and validation of AI models.

The research team conducted an extensive review of the scientific literature to identify appropriate imaging protocols, segmentation strategies, and machine learning techniques suitable for TMJ analysis. Based on the literature review and preliminary experiments, a modified MobileNet-V2 convolutional neural network (CNN) architecture with transfer learning was selected for the classification task.

The developed AI model was trained to identify different categories of disc position abnormalities, including:

- normal disc position;
- anterior disc displacement with reduction;
- anterior disc displacement without reduction;
- medial and lateral disc displacement.

The dataset was divided into training, validation, and testing subsets. Data augmentation techniques were applied to improve model robustness. The final model achieved a training accuracy of 92% and a test accuracy of 81% for automated TMJ disc displacement classification.

In parallel, a new MRI database was collected, including anonymized TMJ imaging data intended for future AI applications. A segmentation protocol for temporomandibular joint structures was also established to support the development of automated segmentation algorithms for MRI analysis.

The study showed the feasibility of AI-assisted TMJ evaluation and highlighted the potential of deep learning to support clinical diagnosis and educational applications in dentomaxillofacial radiology. Future research activities will focus on expanding the MRI dataset, integrating clinical parameters, and developing explainable AI models for a more comprehensive TMD diagnosis.

The study was finalized and the results were disseminated through scientific presentations at national and international conferences. The activities conducted within this research direction resulted in a published ISI-indexed scientific article.

*Almășan O, Mureșanu S, Hedeșiu P, Cotor A, Băciuț M, Roman R, Team Project Group. An Examination of Temporomandibular Joint Disc Displacement through Magnetic Resonance Imaging by Integrating Artificial Intelligence: Preliminary Findings. Medicina (Kaunas). 2024 Aug 26;60(9):1396. doi: 10.3390/medicina60091396. PMID: 39336437; PMCID: PMC11433800.*

### III. Artificial Intelligence for the Detection of Dental Conditions on Panoramic Radiographs



The TEAM Project supported the development of multiple applications for the automated detection and segmentation of dental conditions on panoramic radiographs. Research activities focused on the creation of annotated imaging datasets, development of deep learning models, external validation procedures, and preliminary evaluation of AI-assisted diagnostic tools for clinical use.

### 3.2.1 Teeth and Carious Lesion Segmentation

One of the main research directions focused on the automated segmentation of teeth and carious lesions on panoramic radiographs. A dedicated computer-aided detection system (CariSeg), was developed using a two-step deep learning approach. The first stage involved teeth segmentation using a U-Net architecture, followed by carious lesion segmentation using an ensemble of three neural network architectures: U-Net, Feature Pyramid Network (FPN), and DeepLabV3.

The study included the creation and annotation of dedicated imaging datasets, including 150 panoramic radiographs for carious lesion segmentation and over 1,000 radiographs used for teeth segmentation training. Preprocessing and augmentation techniques were implemented, including automatic cropping around the dental arches, gamma correction, rotation, scaling, and contrast adjustments, to improve model generalizability and reduce overfitting.

The developed framework achieved strong performance for both teeth and carious lesion segmentation, obtaining 94.89% accuracy and an 88.5% Dice score for teeth segmentation, as well as 99.42% accuracy and a mean Dice coefficient of 68.2% for carious lesion segmentation.

The results of this research were published in the article:

*Mărginean AC, Mureșanu S, Hedeșiu M, Dioșan L. Teeth segmentation and carious lesions segmentation in panoramic X-ray images using CariSeg, a networks' ensemble. Heliyon. 2024 May 10;10(10):e30836. doi: 10.1016/j.heliyon.2024.e30836. PMID: 38803980; PMCID: PMC1128823*

Additional experiments were conducted to optimize segmentation performance and improve the generalizability of the models through preprocessing, augmentation and validation.

### 3.2.2 Automated Detection of Multiple Dental Conditions

A second research direction focused on the automated detection of multiple dental conditions using object detection algorithms based on the YOLO architecture.

An imaging dataset consisting of 1,628 panoramic radiographs was retrospectively collected and manually annotated by calibrated examiners. An additional multicenter dataset of 180 panoramic radiographs was assembled for external validation.

The developed AI model was trained to identify a broad spectrum of dental conditions and treatments, including carious lesions, periapical lesions, periodontal bone loss, impacted teeth, root fragments, root resorption, prosthetic restorations, endodontic treatments, implants, orthodontic appliances, and surgical devices. Annotation reliability demonstrated excellent inter-observer agreement, with an ICC value of 0.91.

The final YOLOv8 model showed strong performance for the detection of implants, endodontic treatments, impacted teeth, orthodontic devices, and surgical hardware during internal validation. External validation highlighted the challenges associated with multicenter datasets and emphasized the importance of improving model generalizability for subtle lesions such as early caries and periodontal bone loss.



The research activities resulted in the following publication:

*Mureșanu S, Hedeșiu M, Iacob L, Eftimie R, Olariu E, Dinu C, Jacobs R, on behalf of Team Project Group. Automating Dental Condition Detection on Panoramic Radiographs: Challenges, Pitfalls, and Opportunities. Diagnostics (Basel). 2024 Oct 21;14(20):2336. doi: 10.3390/diagnostics14202336. PMID: 39451659; PMCID: PMC11507083.*

Additional experiments were performed using newer object detection architectures, including YOLOv11 and RT-DETR-X\_2024, in order to improve detection accuracy and robustness. Comparative analyses between different model architectures were initiated as part of the optimization process.

The experiments resulted in one published paper:

Eftimie S, Ileni T, Iacob L, Hedeșiu M, Dioșan L. Tooth-level detection and mapping of dental pathologies on panoramic radiographs using YOLOv11 and RT-DETR. *MethodsX*. 2025 Oct 28;15:103696. doi: 10.1016/j.mex.2025.103696. PMID: 41277983; PMCID: PMC12637385.

A new graphical user interface for end-users was also initiated. The developed model was integrated into the DentiHub platform under the name “AIPredictor”, allowing educational use, real-time testing, and further validation of the algorithm directly within the platform environment.

A new multicenter external validation study was initiated using datasets collected from different imaging centers. The performance of the AI model is currently being compared with the interpretations of senior dental students and dentists with different levels of clinical experience.

### **3.2.3 Detection of Maxillofacial Cysts and Tumors**

The project also supported the development of AI algorithms for the identification and classification of maxillofacial cysts and tumors on panoramic radiographs and CBCT images.

A pilot dataset containing 172 patients was collected. Lesions included ameloblastomas, dentigerous cysts, radicular cysts, residual cysts, odontogenic keratocysts, simple bone cysts, odontomas, and osteomas. The lesions were manually annotated on panoramic radiographs using bounding-boxes and the dataset was divided into training, testing, and validation subsets.

Multiple deep learning experiments were conducted using MobileNet architectures, with MobileNetV3Large achieving the highest classification accuracy of approximately 0.88. In parallel, manual segmentation of lesions on CBCT images was initiated to support the future development of automated segmentation algorithms based on U-Net and nnU-Net frameworks.

A preliminary Streamlit-based user interface was developed to allow image upload, region-of-interest selection, automated lesion prediction, and retrieval of visually similar cases. The UI is currently available on the DentiHub platform.

Research activities in this area were presented at international scientific congresses, including the International Association of Dentomaxillofacial Radiology (IADMFR) Congress, London, June 2025, and DDS Venice, October 2025. The scientific manuscript describing the developed model has been submitted for publication.

### **3.2.4 AI-Based Detection of Maxillofacial Lesions on CBCT**

Research activities were extended toward the development of artificial intelligence algorithms for the detection and classification of maxillofacial cysts and tumors on CBCT examinations. A dedicated database containing 120 CBCT examinations with manually segmented intraosseous lesions was



developed. Lesion annotations were stored in nrrd format to support three-dimensional analysis and segmentation tasks.

The proposed methodology is based on two 3D convolutional neural network (3D CNN) architectures and includes two principal components: automated lesion detection and lesion classification. Experiments were conducted to optimize segmentation performance. Preliminary results demonstrated a high overlap between automated and reference segmentations, reaching a Dice score of approximately 0.8. Current research activities focus on the development of the lesion classification component of the framework. Partial results of the study were presented at DDS Venice, October 2025.

#### IV. Digital Dentistry and 3D Printing Applications

The project supported research activities focused on the integration of digital workflows and additive manufacturing technologies into aesthetic dental rehabilitation. The research explored the use of intraoral scanning, digital smile design, CAD/CAM systems, and 3D printing technologies for the fabrication of minimally invasive prosthetic devices.

One study investigated the use of 3D-printed Snap-On Smile devices as a short-term aesthetic rehabilitation solution. It included both a literature review and a clinical case report evaluating the indications, manufacturing techniques, advantages, and limitations of these removable prosthetic devices.

The literature review was conducted according to PRISMA-P guidelines and analyzed studies published between 2000 and 2024. The review assessed digital manufacturing workflows involving intraoral optical impressions, virtual smile planning, CAD modeling, and additive manufacturing.

A clinical case was developed within the project for a 59-year-old patient requiring immediate aesthetic rehabilitation. The complete digital workflow included intraoral scanning with Trios 3, digital smile design planning, CAD modeling in Exocad, and fabrication of the prosthetic devices through DLP 3D printing technology using Flexcera Smile Ultra+ resin.

The study illustrates the potential of digital dentistry technologies to provide rapid, minimally invasive, and personalized aesthetic rehabilitation while preserving dental structures and reducing treatment time. These activities contributed to the implementation of advanced digital workflows within the research and educational framework of the TEAM Project.

Additional research activities evaluated the dimensional accuracy of fused deposition modeling (FDM)-printed dental models manufactured using different nozzle diameters. Reference STL datasets representing maxillary and mandibular dental arches were printed using a Bambu Lab X1 Carbon printer with 0.2 mm and 0.4 mm nozzles. Dimensional accuracy was assessed using root mean square (RMS) deviation obtained through three-dimensional surface comparison. The study demonstrated improved dimensional accuracy for models printed using smaller nozzle diameters, while mandibular models showed higher dimensional stability compared with maxillary models. These findings contribute to the optimization of low-cost additive manufacturing workflows in dentistry.

These activities resulted in the following publications:

*Burde AV, Frățilă C, Varvară EB, Varvară AV, Short-term aesthetic rehabilitation with 3d printed snap-on smile devices – literature review and a case report, Romanian Journal of Oral Rehabilitation, Vol. 16, No.2 April-June 2024, DOI: 10.6261/RJOR.2024.2.16.58*



Manole MC, Burde AV, Grecu A, Hedeșiu M, Sinescu C. The effect of nozzle diameter on the dimensional accuracy of FDM-printed dental models. *Med Evol.* 2026;32(1). doi:10.70921/medev.v32i1.2030

## V. Automated Segmentation and Virtual Surgical Planning

The project supported multiple research activities focused on virtual surgical planning (VSP), automated anatomical segmentation, and AI-assisted image analysis for implantology and maxillofacial surgery applications. These activities aimed to develop advanced digital workflows integrating CBCT imaging, artificial intelligence, and three-dimensional anatomical modeling in order to improve surgical precision, risk assessment, and personalized treatment planning.

### AI for Implantology Treatment Planning

One of the principal research directions focused on the development of AI-assisted implantology planning workflows based on CBCT examinations. A dedicated database containing 100 paired preoperative and postoperative CBCT datasets was assembled. Research activities included manual segmentation of relevant anatomical structures, such as the alveolar bone, teeth, maxillary sinus, mandibular canal, and dental implants, using 3D Slicer software. These datasets are currently being used for the development and training of artificial intelligence algorithms for automated implant planning and virtual surgical guidance.

Additional studies investigated the automated detection and segmentation of the medial lingual foramen (MLF) on CBCT images using U-Net-derived deep learning architectures. A total of 106 CBCT examinations were retrospectively analyzed for morphometric assessment and AI model development. The best-performing model achieved a Dice score of 0.79, precision of 0.88, and recall of 0.73, while external validation demonstrated a Dice score of 0.81 and successful identification of the MLF in 90% of external validation cases. Partial results were presented at DDS Venice 2025, and the manuscript was submitted for publication.

### Automatic Segmentation of the Anterior Ethmoidal Artery on CBCT

Research activities were initiated for the development of artificial intelligence algorithms for the automatic segmentation and classification of the anterior ethmoidal artery (AEA) on CBCT examinations, with potential applications in image-guided endoscopic sinus surgery and surgical risk assessment. The study included 130 CBCT examinations with bilateral manual segmentations performed in 3D Slicer, as well as an external validation dataset of 20 CBCT scans acquired from different imaging centers.

The proposed AI framework combined U-Net and UNet++ architectures with EfficientNet encoders and attention mechanisms for automatic AEA detection and segmentation. Preliminary results demonstrated good segmentation performance, achieving a Dice coefficient of approximately 0.80, with successful identification of the artery on external validation datasets.

The study additionally included anatomical classification of the AEA in relation to the ethmoidal roof in order to support surgical planning and risk assessment during functional endoscopic sinus surgery. Partial results were presented at ECR Vienna 2026, while manuscript preparation and further validation activities are ongoing.

### Automated Orbit Segmentation for Patient Specific Implants

The project additionally contributed to the development of automated segmentation tools for orbital reconstruction and virtual surgical planning in maxillofacial surgery. A multicenter study using the nnU-



Net framework was performed on a dataset containing more than 1000 expert-segmented orbital CT examinations collected from multiple international centers. The developed model achieved high segmentation accuracy and enabled rapid automated orbital reconstruction planning, supporting patient-specific surgical workflows and personalized implant design. The results were published in the International Journal of Oral and Maxillofacial Surgery as:

*Rashad A, Beyer M, Eftimie S, Hinrichs-Puladi B, Vladu O, Xie K, Truhn D, Thieringer FM, Gander T, Hölzle F, Egger J, Ilesan RR. Pioneering fully automated bony orbit segmentation: an in silico nnU-Net multicentre approach. Int J Oral Maxillofac Surg. 2026;55(5):542–548.*

## VI. Robotic-Assisted Surgery and Dynamic Navigation Systems

The TEAM Project supported interdisciplinary research activities focused on robotic-assisted implant surgery and dynamic navigation systems for dentistry. These studies aimed to improve surgical precision, implant positioning accuracy, and intraoperative safety through the integration of CBCT imaging, optical tracking systems, force-feedback control, and robotic guidance technologies.

One research direction focused on the development of a vision-guided robotic system for dental implant surgery. The proposed framework integrated preoperative CBCT examinations, real-time visual guidance from a robot-mounted camera, and force-feedback control mechanisms in order to improve spatial positioning accuracy during implant placement. A personalized marker-holder guide derived from the patient CBCT examination was used for calibration and registration between the patient and the robotic system. Experimental validation performed on 3D-printed mandibular models demonstrated improved implant positioning accuracy compared with conventional manual procedures, supporting the feasibility of robotic-assisted implant surgery in anatomically complex cases. The results of the study were published in the Journal of Clinical Medicine as:

*Pisla D, Bulbucan V, Hedeșiu M, Vaida C, Zima I, Mocan R, Tucan P, Dinu C, Pisla D, TEAM Project Group. A Vision-Guided Robotic System for Safe Dental Implant Surgery. J Clin Med. 2024;13(21):6326.*

A second study investigated real-time motion compensation during dynamic implant surgery procedures. The developed framework integrated optical motion tracking with a collaborative robotic system in order to maintain alignment between the surgical instrument and the planned implant trajectory despite patient head movement. Experimental validation was performed using controlled rotational, translational, and combined motion patterns on a robotic simulation platform. The system achieved submillimetric positioning accuracy, low latency, and stable compensation behavior under dynamic conditions, demonstrating the potential of robotic motion compensation systems for improving surgical safety and precision during implant placement procedures. The study was published in the Journal of Clinical Medicine as:

*Pisla D, Bulbucan V, Hedeșiu M, Vaida C, Cailean A, Mocan R, Tucan P, Dinu C, Pisla D, TEAM Project Group. Real-Time Motion Compensation for Dynamic Dental Implant Surgery. J Clin Med. 2025;14:6429.*

## VII. Low-Dose CT Enhancement

Research activities within the TEAM Project also explored deep learning approaches for improving the quality of low-dose CT examinations and supporting radiation dose reduction strategies in medical imaging. One study investigated a novel deep learning framework, ConvU-NExT, combining ConvNeXt and U-Net architectures for denoising low-dose CT images while preserving anatomical details.



The proposed model demonstrated significant noise reduction and improved performance compared with conventional U-Net approaches, supporting potential applications in dose optimization and medical image enhancement workflows.

The results were published in IET Image Processing as:

*Iacob LM, Oniț RD, Groza A, Varan A, Mureșanu S, Hedeșiu M, et al. ConvU-NExT: An asymmetrical encoder–decoder for denoising low dose CT. IET Image Process. 2026;20(1):e70317.*